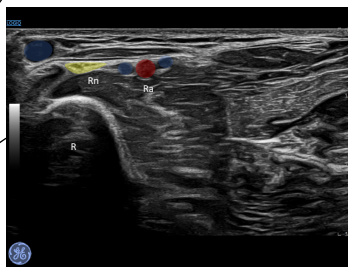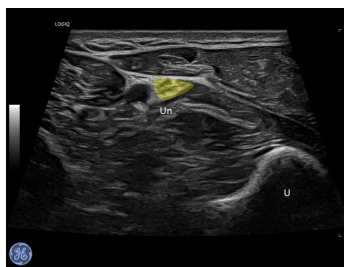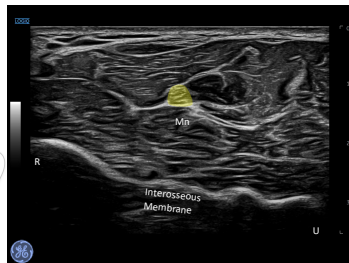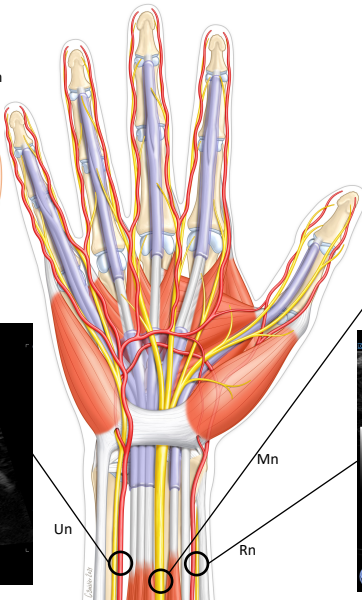
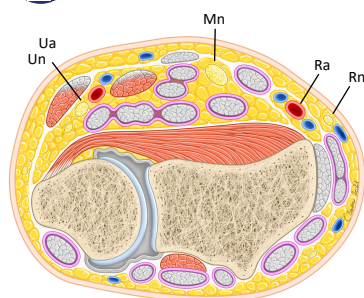


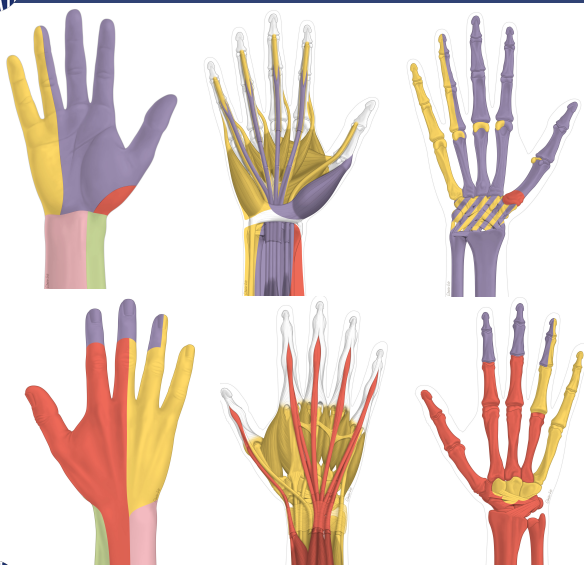ANATOMY – SONOANATOMY

Illustrator : Charles Boistier



INNERVATION



Legends

- ulnar nerve
- median nerve
- radial nerve
- Lateral cut. nerve of the forearm
- Medial cut. nerve of the forearm
- Un, ulnar nerve
- Mn, median nerve
- Rn, radial nerve
- Ua, ulnar artery
- Ra, radial artery
- U, Ulna
- R, Radius



vers les videos

HOW TO CHOOSE THE RIGHT COMBINATION* : HAND & FINGERS

Thumb	Radial + Median
2nd finger	Radial + Median
3rd finger	Radial + Median + Ulnar
4th finger	Median + Ulnar +/- Radial
5th finger	Ulnar

Hand - dorsal surface	Ulnar + Radial
Hand - palmar surface	Median + Ulnar

*The existence of numerous nerve anastomoses and anatomical variations may explain the failures of these combinations. TRONCULANT (association of distal TRONCULAR blocks and WALANT, both under US) could improve efficiency.